

An Unusual Case: Pruritic Vulvar Syringoma

Mehmet DOLANBAY¹, Mehmet Serdar KÜTÜK¹, Semih ULUDAĞ¹, Mahmut Tuncay ÖZGÜN¹, Ayça Nazlı BULUT¹,
Turhan ÖKTEN²

Kayseri, Turkey

Vulvar pruritus and pain are common symptoms for visiting a gynaecologist. A 37-year-old woman presented with a six months history of vulvar papular pruritic lesion unresponsive to topical antifungal and anti-inflammatory therapy. Cutaneous examination of vulva showed multiple, bilaterally, 1-4 mm sized, skin-colored papules over the labia major. Histopathological examination revealed syringoma. She was treated with mild potent corticosteroid cream and oral antihistaminics. Pruritus was improved within two weeks but cutaneous papules were not. Though very rare, vulvar syringoma should be kept in mind in the differential diagnosis of persistent and severe vulvar pruritus.

Keywords: Syringoma, Vulva, Pruritus, Corticosteroid, Cutaneous papule

Gynecol Obstet Reprod Med 2013;19:101-102

Introduction

Vulvar pruritus and pain are common symptoms for visiting a gynaecologist or dermatologist. It is frequently associated with vulvar dermatoses, contact dermatitis, lichen sclerosis and vulvar intraepithelial neoplasia. Rarely vulvar syringoma; a benign tumour of eccrine sweat glands; may be the cause of pruritic vulva. Consequently it is necessary to make histopathological evaluation for diagnosis of pruritic papular lesions for efficient treatment and excluding the possibility of early stage cancer.¹

Case Report

A 37-year-old woman presented with a six months history of papular pruritic vulvar lesion unresponsive to topical antifungal and anti-inflammatory therapy. There was no history of allergy and contact sensitization. In her gynaecological examination cervix, uterus and ovaries were normal. Cutaneous examination of vulva showed multiple, bilaterally, 1-4 mm sized, skin-colored papules over the labia major (Figure 1). Pathological sampling was done by the excision of the suspicious lesion and histopathological examination revealed findings consistent with syringoma (Figure 2).

¹Erciyes University Faculty of Medicine, Department of Obstetric and Gynecology and ²Department of Pathology, Kayseri

Address of Correspondence: Mehmet Dolanbay
Erciyes University, Faculty of Medicine
Department of Obstetrics and
Gynecology Kayseri, Turkey
mdolanbay@erciyes.edu.tr

Submitted for Publication: 05. 06. 2013

Accepted for Publication: 06. 08. 2013

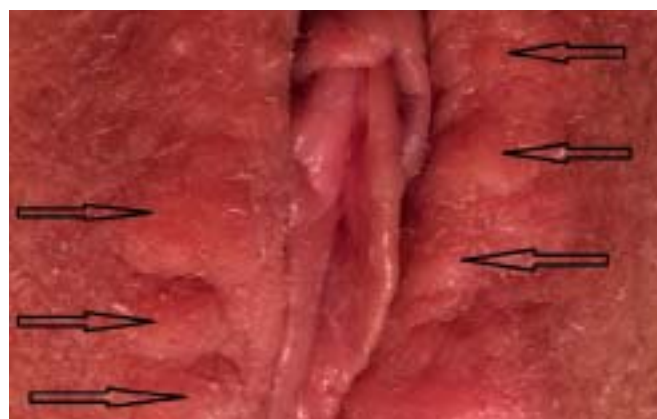


Figure 1: Black arrows; Multiple skin-colored papules over labia majora

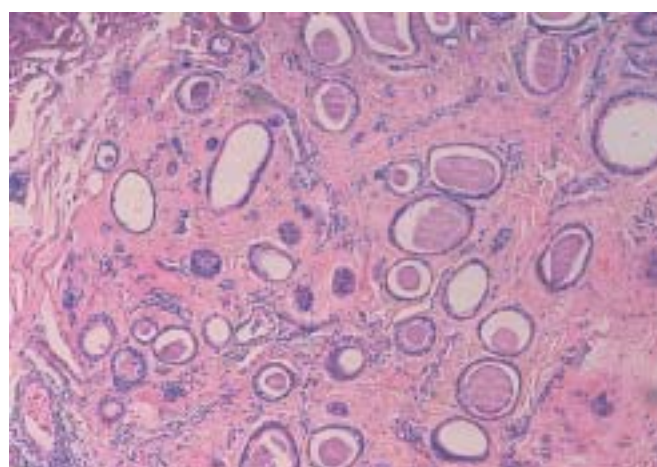


Figure 2: Dilated cystic sweat ducts embedded in a fibrous stroma (H&E, ×100)

Discussion

Syringomas are benign tumours of eccrine sweat glands that appear as multiple, small sized, skin-colored to transparent soft or firm papules. The lesions frequently involve the face, upper cheeks and neck of middle-aged women; however, there are other, more unusual sites, such as the vulva.² There is no association with systemic diseases, but well-known association between syringomas and Down syndrome was manifested. Familial cases have rarely been reported but inheritance is not exactly defined.³

Syringomas of the vulva are usually bilateral, symmetrical and asymptomatic but in some cases severe pruritus in the genital region may be the main symptom. In the published cases of vulvar syringomas, pruritus may be severe in menstruation, summertime and pregnancy.⁴

In the differential diagnosis of syringoma epidermal cysts, steatocystoma multiplex, condyloma, lichen planus, Fox-Fordyce disease and lichen simplex chronicus should be considered. Epidermal cysts, when multiple, could be concerned with syringoma. They are usually much more yellow in appearance, fewer in number and often show characteristic central punctuation. Fox-Fordyce disease can mimic syringoma of the vulva but lesions are smaller and more conical.⁵ Because the appearance of vulvar syringoma is nonspecific, histology is key to establishing the diagnosis and ruling out malignancy. Microscopic findings of syringoma reveal a normal epidermis and dilated cystic sweat ducts embedded in a fibrous stroma in the dermis. Some ducts present characteristic small, comma-shaped epithelial cell tails that resemble a tadpole.⁶ In our case, the clinical symptoms and physical examination excluded other common causes of vulvar pruritus such as candidiasis, pediculosis, allergic contact dermatitis, lichen sclerosis and atrophic lichen. And initial diagnosis was done with histopathology.

In vulvar syringomas treatment modalities include, oral tranilast, topical atropine, excision, electro-desiccation, curettage, laser and cryotherapy.²⁻⁷ In principle, the treatment of pruritic vulvar dermatoses should be initially attempted with non-invasive, topical therapies. However, only a minority of patients achieve adequate control of pruritus with topical corticoids, with or without oral antihistamines. Taken into account the fact that vulvar syringomas are mainly seen in middle aged women, destructive therapies such as electro-desiccation, and laser, should be reserved as a last resort. In cases with deep subcutaneous involvement, it may be necessary to make excision procedure which may lead to scar formation and deformity. In our patient we used mild potent corticosteroid cream and oral antihistaminic therapy as a first line ther-

apy. Fortunately, pruritus improved in two weeks but cutaneous papules persisted.

Though very rare, vulvar syringoma should be kept in mind in the differential diagnosis of persistent, and severe vulvar pruritus, and the diagnosis should be confirmed with biopsy and histopathological examination

Nadir Bir Olgu: Kaşıntılı Vulvar Siringoma

Vulvar kaşıntı ve ağrı jinekoloğa başvuruda yaygın semptomlardır. Bu makalede altı ay boyunca topikal antifungal ve anti-enflamatuvar tedaviye cevap vermeyen papüler görünümde, kaşıntılı vulvar lezyon öyküsü olan 37 yaşında bir hasta sunulmuştur. Vulvar bölgenin cilt muayenesinde labium majörler üzerinde birden fazla, çift taraflı, 1-4 mm boyutlarında, deri renginde papüller izlendi. Histopatolojik inceleme siringoma olarak değerlendirildi. Hasta orta potent kortikosteroid kremler ve oral antihistaminikler ile tedavi edildi. Kaşıntı iki haftada ortadan kayboldu ancak papüler lezyonların görüntüsünde değişiklik izlenmedi. Nadir olarak görülmekle beraber, persiste ve şiddetli vulvar kaşıntının ayırıcı tanısında vulvar siringoma mutlaka akılda tutulmalıdır.

Anahtar Kelimeler: Siringoma, Vulva, Kaşıntı, Kortikosteroid, Kutanöz papül

References

1. Huang YH, Chuang YH, Kuo TT, Yang LC, Hong HS. Vulvar syringoma: a clinicopathologic and immunohistologic study of 18 patients and results of treatment. *J Am Acad Dermatol* 2003;48:735-9.
2. Marzano AV, Fiorani R, Girgenti V, Crosti C, Alessi E. Familial syringoma: report of two cases with a published work review and the unique association with steatocystoma multiplex. *J Dermatol* 2009;36:154-8.
3. Urban CD, Cannon JR, Cole RD. Eruptive syringomas in Down's syndrome. *Arch Dermatol* 1981;117:374-5.
4. Agrawal S, Kulshrestha R, Rijal A, Sidhu S. Localized vulvar syringoma causing vulvar pruritus and venerophobia. *Australas J Dermatol* 2004;45: 236-7.
5. Turan C, Ugur M, Kutluay L, et al. Vulvar syringoma exacerbated during pregnancy. *Eur J Obstet Gynecol Reprod Biol* 1996;64:141-2.
6. Carneiro SJ, Gardner HL, Knox JM. Syringoma: Three cases with vulvar involvement. *Obstet Gynecol* 1972; 39:95-9.
7. Garman M, Metry D. Vulvar syringomas in a 9-year-old child with review of the literature. *Pediatr Dermatol* 2006;23:369-72.